



Published By : IVAA
the Indonesian Vascular Access Association

Angioplasty experience for central venous stenosis in hemodialysis patients: a case series



Nyoman Saka Ranuartha^{1*}, Danang Himawan Limanto¹, Ketut Putu Yasa²

ABSTRACT

Introduction: Central venous stenosis is a common case in patients with renal failure or end-stage renal disease who have a history of dialysis, which requires vascular access. The currently available techniques for managing central venous stenosis are endovascular intervention with angioplasty and stent placement. Although open surgical treatment has shown durability in the past, it was correlated with significant morbidity. One of the techniques describes the antegrade technique of endovascular intervention.

Objective: To report the treatment of central venous stenosis in hemodialysis patients with endovascular intervention angioplasty.

Case description: In this study present 5 cases of central venous stenosis in patients with hemodialysis. In this case series, the patient complained that had a history of swelling in the upper arm unilateral. Diagnostic with catheterization, there was stenosis of the subclavian vein and innominate. This study performed the endovascular management experience with the preferred treatment for central venous stenosis to perform revascularization procedures which is percutaneous transluminal angioplasty (PTA) with balloon angioplasty.

Conclusions: Management of central venous stenosis in patients with hemodialysis can be presented effectively and safely using angioplasty which results in low rates of complication and usually has a shorter length of stay post-procedural.

Keywords: angioplasty, central venous stenosis, endovascular intervention, hemodialysis.

Cite This Article: Ranuartha, N.S., Limanto, D.H., Yasa, K.P. 2023. Angioplasty experience for central venous stenosis in hemodialysis patients: a case series. *Journal of Indonesia Vascular Access* 3(1): 11-14. DOI : 10.51559/jinava.v3i1.33

¹Thorax, Cardiac and vascular surgery department, Faculty of Medicine, Universitas Airlangga;

²Division of Thorax Cardiac Vascular and Endovascular Surgery, Department of Surgery, Universitas Udayana, Denpasar, Bali.

*Corresponding to:

Nyoman Saka Ranuartha;
Thorax, Cardiac and vascular surgery department, Faculty of Medicine, Universitas Airlangga;
renoranuartha@gmail.com

Received: 2022-11-26

Accepted: 2023-01-08

Published: 2023-02-17

INTRODUCTION

Central venous stenosis is a common case as a complication in renal failure or end-stage renal disease patients who have a history of the placement of vascular access for dialysis. Vascular access for dialysis has many complications in end-stage renal disease patients, as a common complication is central veins injured in the placement of intravascular devices for the performance of hemodialysis. Therapy for central venous stenosis can be open surgical treatment or endovascular intervention.^{1,2}

Percutaneous transluminal angioplasty (PTA) is chosen as the treatment for central venous stenosis because of the complexity of surgical treatment and its association with significant morbidity. This is also recommended by the Kidney Disease Outcome Quality Initiative (KDOQI) for symptomatic patients with end-stage renal disease or renal failure in hemodialysis.^{3,4} Developments in technology and medical science in endovascular revascularization

therapy provide the best therapeutic options for patients. Revascularization, with open surgical procedures or PTA, should be considered based on the recommendations of the American College of Cardiology. In fact, angioplasty is recommended for patients with central venous stenosis because associated patients usually have a lower incidence of comorbidities and a shorter length of stay after surgery, so PTA is the treatment of choice.^{1,5,6}

This study was performed at Soetomo Public Hospital, Airlangga University, Surabaya. This case series study aims to report our experience in angioplasty management to maintain patients with central venous stenosis with renal failure or end-stage renal disease who had a history of the placement of vascular access for dialysis. However, this study found that they have comorbidities of hypertension. Over the past few years, several techniques have been developed to provide endovascular intervention for central venous stenosis. We describe our

experience with endovascular intervention angioplasty for crossing the lesion of central venous stenosis and performing revascularization procedures with balloon angioplasty.

CASE DESCRIPTION

The study of this case series performed 5 patients with central venous stenosis with renal failure or end-stage renal disease who had a history of the placement of vascular access for dialysis. All patients had a history of temporary hemodialysis catheter placement in the left and right internal jugular veins, subclavian and femoral veins, and arteriovenous fistula of maintenance hemodialysis. Their ages ranged from 30 years to 70 years. The maintenance before the procedure had a duration of about 3 to 12 months. Patient complained that had a history of swelling of the upper arm unilateral. Diagnostic with catheterization, there was stenosis of the subclavian vein and innominate.

The upper extremity vein is the access

used for the antegrade wire from the AV fistula site in the procedure with the antegrade technique. Then the lesion is crossed antegrade, and the guidewire that crosses the lesion is exteriorized using a snare. This technique better supports crossing the lesion with a balloon or stent. A 5F Judkins right (JR) sheath was applied in this procedure through the venous division of the right upper limb or the AV vein fistula in the left upper limb. The location of the stenosis can be localized by using an arteriovenous fistulogram. Evaluation of the site diameter of stenosis would be carried out after the wire had successfully passed through the vein stenosis, then followed by administration of heparin 5000 IU. The balloon catheter was threaded through the guidewire, and the lesion was predilated. The guidewire passing through the antegrade was pulled back after the balloon was positioned across the lesion (Figure 1, Figure 2, Figure 3). Inflation was given to the balloon angioplasty for 60-120 seconds.

The venogram was executed through a Judkins catheter across the left brachial vein. Post balloon angioplasty, we looked for any elastic recoil from the lesion. If there was significant elastic recoil of the lesion, stent placement was performed after balloon dilatation, and stenosis at the lesion site remains >50%. After evaluating the venogram, there is residual stenosis, and it is decided to insert a balloon catheter and then provide inflations for 60- 120 seconds. A venogram was performed through the Judkins catheter to ensure the resulting flow was good and minimally stenosis. Full effacement of the stent for post-dilated balloon angioplasty was performed to match the size of the vessel. If brisk contrast flow was set up through the catheter, the procedure could be considered successful. Vascular sheaths and guidewires were removed from the femoral and brachial sites.

Patients were observed in the high-care unit and could be discharged the following day. Patients were clinically followed up for AVF dysfunction during hemodialysis to ensure there was no problem in hemodialysis treatment. Out of the 4 patients with subclavian stenosis and 1 innominate stenosis, in 4 (80%)

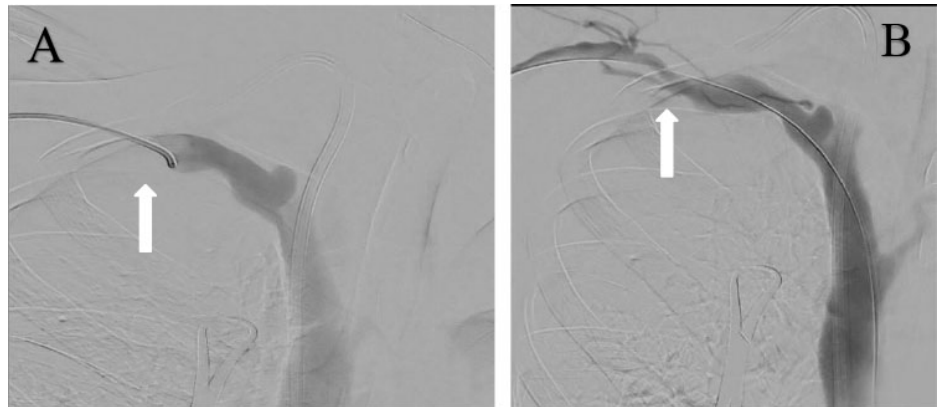


Figure 1. Antegrade technique. 1A: The guidewire passed antegrade through the right upper limb and location stenosis of segment subclavian. **1B:** Post-balloon dilatation with the brisk flow of contrast.

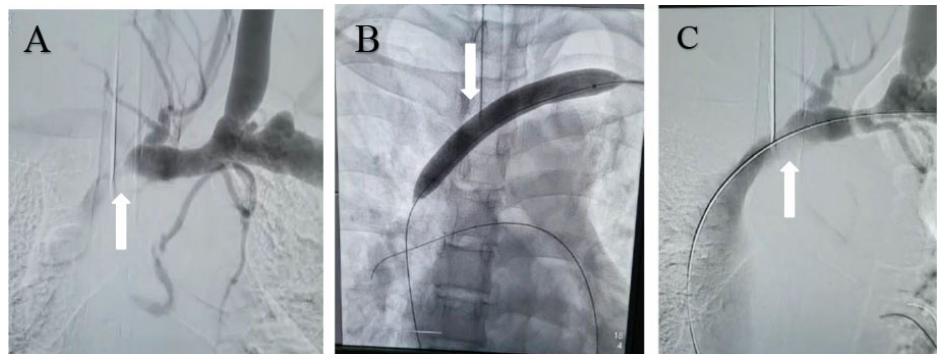


Figure 2. Antegrade technique. 2A: The guidewire passed antegrade through the left upper limb and location stenosis of segment innominate. **2B:** Lesion crossing by catheter and balloon dilatation. **2C:** Post balloon dilatation with the brisk flow of contrast.

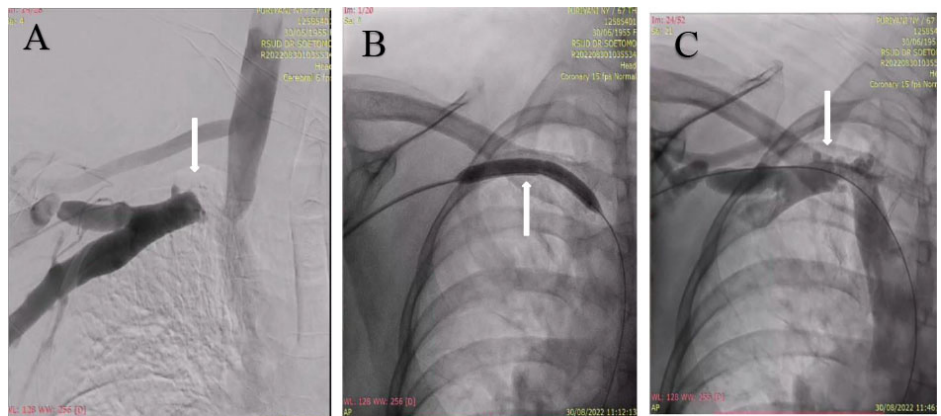


Figure 3. Antegrade technique. 3A: The guidewire passed antegrade of the right upper limb and location stenosis of segmentsubclavian. **3B:** Lesion crossing by catheter and balloon dilatation. **3C:** Post balloon dilatation with the brisk flow of contrast.

patients, the lesions could be crossed antegradely. Almost total occlusion of the right subclavian occurred in one (20%) patient. The lesion could be crossed with an antegrade approach, but to establish successful and rapid contrast

flow, it required 2 balloonings through the catheter. Complete effacement of the ballooning angioplasty was achieved with brisk contrast flow and no remaining stenosis in all patients. There were no problems related to dialysis flow or

immediate post-procedure complications during the 2-month clinical follow-up period.

DISCUSSION

Central venous stenosis is common in renal failure or end-stage renal disease patients with a history of the placement of vascular access for dialysis. Hemodialysis is widely used in various developing countries and is an optimal therapeutic choice. This initiates dialysis using a catheter. Consequently, central vein stenosis is common due to central vein injury.^{1,7}

There are two main factors associated with the cause of central venous stenosis in patients with dialysis: (1) hemodialysis with temporary central venous catheterization and (2) arteriovenous fistula formation, which induces a high-flow state with a resultant area of increased turbulence. Central venous stenosis can complicate the maintenance of hemodialysis access substantially by increasing arteriovenous access pressures and causing local morbidity by generating extremity, neck, chest, and even facial swelling.^{2,8}

The currently available techniques for managing central venous stenosis are endovascular intervention with angioplasty and stent placement. Although open surgical treatment had shown durability in the past, it was correlated with significant morbidity.^{1,7}

PTA is the recommended choice for the treatment of central venous stenosis. However, another choice is open surgery can be treated for central venous stenosis if the stenosis site is difficult to cross by PTA. The technical success of the interventional treatment of central venous stenosis is explained by two main aspects. These are crossing the segment of stenosis and performing the procedure of revascularization.⁵ Pass the guidewire across the vein, stenosis is crossing, and revascularization is to locate the balloon and the stent across the stenosis, then do the angioplasty of the site of stenosis. The length of the stenosis or occluded segment of the vein, the elasticity of the lesion, and tortuosity are the factors defining the difficulty in crossing the lesion and performing the revascularization procedure.^{7,9,10}

To give interventions for central venous stenosis, the single direction technique was performed, single approach technique is required, which may achieve higher success for short occluded segments or venous stenosis and target lesions. Through the antegrade approach, single access can be achieved from the site of the AV fistula.^{5,11} Revascularization is the second step of the interventional procedure that significantly contributes to the success of the procedure and the overall time of operation. The unidirectional single-wire technique can support the passage of angioplasty balloons and stents across the lesion in cases of shorter and more tender lesions. However, the unidirectional approach may not give sufficient support to pass the stent and balloon through the narrow segment of the long, occluded, and tortuous segment.^{11,12}

PTA has developed into a recommended treatment modality for central venous stenosis with or without stent placement. Agarwal et al., in 2015, described the result of endovascular intervention for central venous stenosis with a single approach technique, which has a good result and higher success for a short occluded segment or vein stenosis.^{1,10,13-17} This study of case series uses of single approach technique of antegrade position to a crossing of the lesion and is in line with the research of Agarwal et al.¹

CONCLUSION

Endovascular intervention with angioplasty deployment is the currently recommended technique available for the treatment of central venous stenosis. Although open surgical treatment had shown durability in the past, it was correlated with significant morbidity. As a result, this study presents primary patency after angioplasty with balloon angioplasty, has a good result with low rates of complication and failed angioplasty as a treatment. This approach by antegrade offers a safer option, is less invasive, and lower postoperative mortality rates. The additional study still needs to evaluate the long-term outcomes. It should be noted that we evaluated the angioplasty procedure of central venous stenosis to set up the flow and decrease venous hypertension. It is important to examine

the limitations of our present knowledge in endovascular intervention for central venous stenosis.

CONFLICT OF INTEREST

The authors state there was no conflict of interest.

FUNDING

No funding was received for the study.

AUTHOR CONTRIBUTION

All authors contributed equally in the writing of this article

ETHICS APPROVAL

This study had been ethically approved by the Ethical commission

REFERENCES

1. Agarwal AK. Endovascular interventions for central vein stenosis. *Kidney Res Clin Pract.* 2015;34:228-232.
2. Thwaites SE, Robless P a. Central vein stenosis in an Asian hemodialysis population. *Asian Cardiovasc Thorac Ann [Internet].* 2012;20(5):560-5.
3. Lok CE, Huber TS, Lee T, et al. KDOQI vascular Access Guideline Work Group. KDOQI clinical practice guideline for vascular access: 2019 update. *Am J Kidney Dis.* 2020;75(4):S 1eS 164, 9 Suppl. (2).
4. National Kidney Foundation. K/DOQI Clinical Practice Guideline for Vascular Access: 2019 update. *Am J Kidney D.*
5. Surowiec SM, Fegley AJ, Tanski WJ, Sivamurthy N, Illig K a, Lee DE, et al. Endovascular management of central venous stenoses in the hemodialysis patient: results of percutaneous therapy. *Vasc Endovascular Surg.* 2015;38(4):349-54.
6. Zhao Y, Cui T, Yu Y, Liu F, Fu P, Zhou L, et al. Successful tunneled catheter placement in a hemodialysis patient with idiopathic multiple central venous stenoses. *Hemodial Int.* 2014;18(1):200-4.
7. Ashwal AJ, Abdul Razak UK, Padmakumar R, UmeshPai Sudhakar M. Percutaneous intervention for symptomatic central vein stenosis in patients with upper limb Arteriovenous dialysis access. *Indian Heart J.* 2018;70:690e698.
8. Agarwal AK, Bhaliavi M, Haddad NJ. Central vein stenosis: a nephrologist's perspective. *Semin Dial.* 2007;20(1):53e62.
9. Huang Y, Chen B, Tan G, et al. The feasibility and safety of a through-and- through wire technique for central venous occlusion in dialysis patients. *BMC Cardiovasc Disord.* 2016;16:250e261.

10. Banshodani M, Kawanishi H, Shintaku S, Moriishi M, Yamashita T, Ago R, et al. Percutaneous transluminal angioplasty for central venous disease in dialysis patients: influence on cardiac function. *J Vasc Access*. 2014;492-497
11. Nayak-Rao S, Ramanna B, Subramanyam K, Shenoy MP, Kamath J. Endovascular intervention for central venous stenosis in hemodialysis patients: a single- center experience. *Indian J Nephrol*. 2020;30:337e341.
12. Gur S, Oguzkurt L, Gedikoglu M. Central venous occlusion in hemodialysis access: comparison between percutaneous transluminal angioplasty alone and Nitinol or stainless-steel stent placement. *Diagn Interv Imaging*. 2019;100(9): 485e492.
13. Tapaneeyakorn J, Inman T, Panpikul T, Wedsart B, Suvikrom J. Vascular access stenosis and central vein obstruction interventions: Five years of experience in ramathibodi hospital. *J Med Assoc Thail*. 2012;95(9):1211-8.
14. Quaretti P, Galli F, Moranarco LP, et al. Stent graft provided superior primary patency for central venous stenosis treatment in comparison with angioplasty and bare metal stent: a retrospective single centre study on 70 hemodialysis patients. *Vasc Endovasc Surg*. 2016;50(4):221e230.
15. Hall HC, Moudgill N, Kahn M, et al. An unusual case of venous hypertension after dialysis access creation. *Ann Vascular Surgical*. 2011;25:983
16. Haage P. Management of central vein stenosis. *Cardiovascular intervent Radiol*. 2009;200
17. Rajan DK, Guimaraes M. Central Venous Occlusion: from simple solutions to advanced techniques. *Endovascular today*. 2012;6:34e38.



This work is licensed under a Creative Commons Attribution