



Published By : IVAA
the Indonesian Vascular Access Association

Case report of a stuck hemodialysis central venous catheter: from endovascular intervention to median sternotomy



Reza Eka Putra^{1,2*}, Prasetyo Edi³, Andreas Andri Lensoen⁴

ABSTRACT

Background: Extended uses of hemodialysis catheters is often associated with thrombosis and fibrosis of the central vein around the catheter. The removal becomes complex when the catheter is stuck in a central vein. This case report presented a complex stage of removing a stuck catheter in the central vein.

Case Report: A 45-year-old man complained of a stuck hemodialysis catheter in the left subclavian vein, which had been placed 8 months previously. An endovascular intervention has been tried using traction and snaring of the catheter tip, but it cannot be removed because the body part of the catheter is firmly attached to the central vein, so we decided to evacuate the catheter using the median sternotomy procedure. We found an adhesion between the left innominate vein's wall and the catheter's body about 4 cm from the catheter tip. The left innominate vein was incised longitudinally while detaching the catheter against the vein. We repair the left Innominate vein without using a graft.

Conclusion: A stuck catheter to the central vein was an unexpected complication due to the removal of the hemodialysis catheter. There are several options for removing a stuck catheter, such as various endovascular interventions and open surgical techniques.

Keywords: A stuck hemodialysis catheter, removal technique, endovascular intervention, median sternotomy.

Cite This Article: Putra, R.E., Edi, P., Lensoen, A.A. 2023. Case report of a stuck hemodialysis central venous catheter: from endovascular intervention to median sternotomy. *Journal of Indonesia Vascular Access* 3(1): 5-7. DOI : 10.51559/jinava.v3i1.27

¹General Practitioner, Faculty of Medicine, Universitas Nusa Cendana, East Nusa Tenggara, Indonesia;

²General Practitioner, Sentra Medika Cislak Hospital – Depok;

³Cardiothoracic Vascular Surgeon, Sentra Medika Cislak Hospital – Depok;

⁴Cardiothoracic Vascular Surgeon, Gatot Subroto Army Hospital – Central Jakarta.

*Corresponding to:

Reza Eka Putra;
General Practitioner, Faculty of Medicine, Universitas Nusa Cendana, East Nusa Tenggara, Indonesia;
rezhaputra0000@gmail.com

Received: 2022-11-20

Accepted: 2023-01-09

Published: 2023-02-13

INTRODUCTION

Central venous catheters (CVC) are used for hemodialysis in many patients.¹ Although the least preferred option, CVC provides an effective short to mid-term alternative in patients for transitory periods until permanent vascular access matures.^{1,2} Unfortunately, prolonged catheter use is frequently linked to thrombosis and fibrosis of the central vein surrounding the catheter, which results in luminal stenosis and vein blockage. Hemodialysis catheter complications related to insertion and their presence as a foreign body have been thoroughly documented.² When the catheter needs to be removed, the removal is usually achieved without difficulty. The removal, however, becomes difficult or futile when the catheter becomes lodged in the central vein.³

Encountering a stuck catheter can be a challenging experience. A complex stage of technique is herein reported on a

patient who underwent an endovascular intervention to open surgery technique to remove a stuck catheter for hemodialysis on the left innominate vein.

CASE PRESENTATION

A 45-year-old man complained of a stuck hemodialysis catheter placed 8 months before his admission to the hospital. The patient has a history of end-stage renal disease (ESRD) and has been undergoing hemodialysis in the last two years. The patient, who had been using a catheter in the femoral vein for a year prior, had a non-tunneled hemodialysis catheter inserted in the left subclavian vein over the previous eight months. While waiting for his vascular access to mature, the patient uses the catheter for hemodialysis, but when the vascular access matures and wants to remove the catheter, the attached catheter is stuck and cannot be removed by standard procedures. A computed tomography scan (CT-Scan) procedure

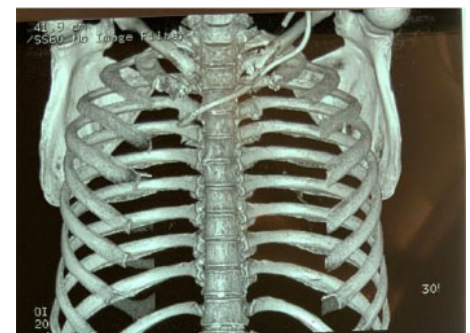


Figure 1. A CVC attached along the left subclavian – left innominate vein.

was conducted to view the location and surrounding structure of the catheter (Figure 1).

The femoral venous route has been used to try an endovascular intervention that involves traction and snaring of the catheter tip (Figure 2). However, it cannot be removed because the body part of the catheter is firmly attached to the central vein, so we decided to evacuate the catheter using the median sternotomy procedure.

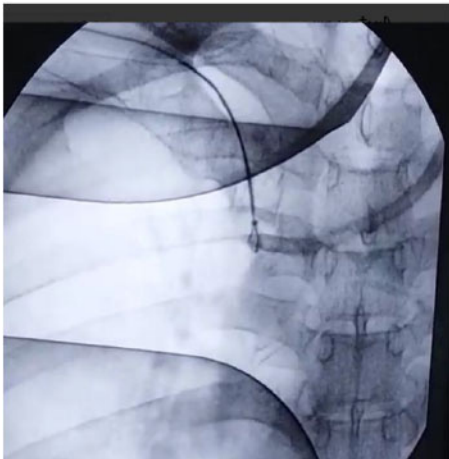

Figure 2. Endovascular technique to remove the stuck catheter using the snaring method.

We found an adhesion between the wall of the left innominate vein and the body of the catheter about 4 cm from the catheter tip (Figure 3), while the catheter tip is placed below the right internal jugular vein. The wall of the left innominate vein was thickening as the catheter went through, and the fibrin sheath was covering the body of the catheter. We decided to incise slowly left the innominate vein longitudinally towards the superior vena cava (SVC) while detaching the catheter against the vein. The catheter was removed; however, neither the left internal jugular nor the left subclavian vein supplied blood to the left innominate vein. We then repair the left innominate vein without using a graft. The patient completely recovered and was discharged home 5 days following surgery.

DISCUSSION

In addition to being utilized for permanent vascular access, CVCs are frequently employed in hemodialysis. Despite their enormous usefulness, these devices have several drawbacks, including getting “stuck” in a vein.^{4,5} In individuals with long-term catheters, varying degrees of adhesion between the catheter and vascular wall might be anticipated. Based on anecdotal case reports, it is difficult to assess the true incidence of blocked catheters.^{2,6}

Histologically, peri-catheter fibrous sheath, vein wall thickening, and thrombus formation following local intima injury

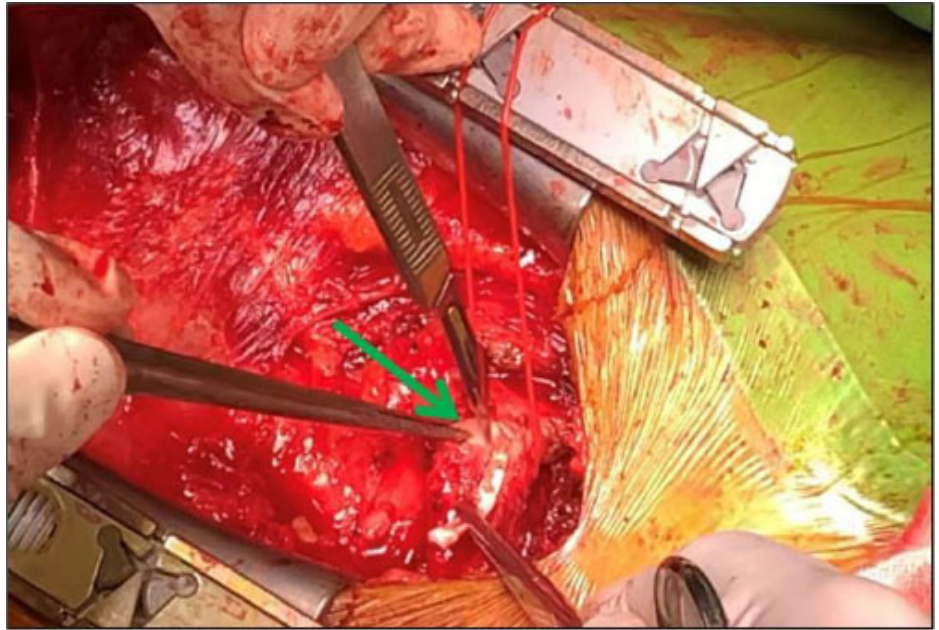


Figure 3. The remaining catheter was covered with a fibrous sheath; green arrow pointing thickened vein wall.

were underlying causes of a stuck catheter to the vein.^{1,7} Subendothelial proliferation can have a role in this case but need further research for more explanation.⁷ Kohler and Kirkman (1998) investigated the significance of catheter tip trauma and related thrombus development in a pig model. It takes multiple injuries to the arterial wall before thrombosis and wall thickening occur. The catheter may abrade the vascular wall where it twists to enter the SVC since the left subclavian insertion has the highest thrombosis rate.⁸

The catheter material may affect complications such as vein thrombosis. In their research, Wildgruber et al. (2016) explained that thrombosis occurred more frequently on polyurethane catheters than on silicone catheters, with a hazard ratio of 22.8% (95% CI: 8.4-62.2). In general, polyurethane catheters have a more rough and irregular surface than other types of catheters, which makes the catheter prone to thrombosis.⁹

In this case study, the patient had an additional circumstance that might have contributed to the catheter being lodged in the central vein. While the patient was waiting for permanent vascular access to mature, extended use of CVC for hemodialysis for nearly 7 months just in one catheter entry site can lead to intimal changes and thickening of the central

vein. Endothelial tissue damage due to the catheter insertion process has not been well explained in this case. A histological examination is required for further explanation.

Endovascular interventions such as traction and snaring of the stuck catheter in the central vein were conducted in several case reports. Field et al. (2013) had an experience due to a stuck catheter in the internal jugular vein. They attempted to remove the catheter using a gooseneck snare via a femoral approach. Unfortunately, the distal segment of the catheter was firmly attached to the vein wall, so they decided to discontinue the procedure and internalize the remaining segment of the catheter attached to the vein wall. Subsequently, the patient died from sepsis-related complications 6 months later.²

Hong (2011) introduced a new endovascular intervention to remove a stuck central vein catheter using the reverse Seldinger catheter insertion method. He removed the blocked catheter from the central vein while dissecting the peri-catheter sleeve of reactive tissue using an introducer sheath covering the catheter inside the vein lumen.³ He also attempted removing a stuck catheter in the central vein using balloon angioplasty inserted through the catheter lumen to

break the adhesion between the catheter and the adherent vein.¹ With this procedure—recently referred to as “Hong’s Technique”—there is no longer any need to perform a sternotomy, cut-down of the access vein, or any other complicated actions.¹

In our case, we tried to remove the catheter using the endovascular method via femoral approach to snare the end of the catheter body and cut down the remaining catheter segment on the entry site. After snaring and gentle traction at the end of the catheter segment, we found that the part of the catheter that firmly attached to the vein wall was the body near the catheter tip, but we cannot ensure how many parts of the catheter which attached to the vein wall, so we discontinued the procedure to prevent the catheter break and made a further injury to the vessel. The patient was planned for an open surgical procedure.

Open procedures like median sternotomies and open heart surgery should be avoided, especially in patients with renal failure and accompanying consequences.⁵ Open procedures were believed to be a reasonable option to avoid potential problems of a retained catheter in the central vein, such as sepsis owing to infection or additional venous thrombosis in this patient, who may have failed the proposed minimally invasive surgery.⁵

In our case, we found four centimeters adhesion in the catheter body segment with a left innominate vein near the right internal jugular vein and thickening of the vein wall and fibrous sheath lining the catheter body. The left innominate vein was slowly incised longitudinally towards SVC while the fibrous sheath was detached

from the catheter body. The catheter was removed from the Innominate vein, and hereafter we repaired the left innominate vein without using a graft.

CONCLUSION

A stuck catheter to the central vein was an unexpected complication due to the removal of the hemodialysis catheter. There are several options for removing a stuck catheter, such as various endovascular interventions and open surgical techniques. More case reports or research about a stuck hemodialysis catheter should be conducted to comprehend our knowledge about this case.

PATIENT’S INFORMED CONSENT

The patient has given informed consent regarding the publication of this case. This study had been ethically approved by the ethical commission.

AUTHOR CONTRIBUTION

All authors contributed equally to the writing of this article.

FUNDING

No funding was received for the study.

CONFLICT OF INTEREST

The authors have no conflicts of interest.

REFERENCES

- Hong JH. A Breakthrough Technique for the Removal of a Hemodialysis Catheter Stuck in the Central Vein: Endoluminal Balloon Dilatation of the Stuck Catheter. *J Vasc Access.* 2011;12(4):381–4. Available from: <http://dx.doi.org/10.5301/jva.2011.8415>
- Field M, Pugh J, Asquith J, Davies S, Pherwani AD. A Stuck Hemodialysis Central venous Catheter. *J Vasc Access.* 2008;9(4):301–3. Available from: <http://dx.doi.org/10.1177/112972980800900415>
- Hong JH. An Easy Technique for the Removal of a Hemodialysis Catheter Stuck in Central Veins. *J Vasc Access.* 2010;11(1):59–62. Available from: <http://dx.doi.org/10.1177/112972981001100112>
- Tristão FR, Moreira RCR, Valle CE Del, Neves GCS. Inadvertent insertion of a venous catheter into the internal thoracic vein: a word of caution. *J Vasc Bras.* 2019;18:e20190097–e20190097. Available from: <https://pubmed.ncbi.nlm.nih.gov/31807130>
- Jafferbhoy SE, Asquith JR, Jeeji R, Levine A, Menon M, Pherwani AD. A stuck haemodialysis central venous catheter: not quite open and shut! *J Surg Case Rep.* 2015;2015(4):rjv032. Available from: <https://pubmed.ncbi.nlm.nih.gov/25848086>
- MORTENSEN A, AFSHARI A, HENNEBERG SW, HANSEN MA. Stuck long-term indwelling central venous catheters in adolescents: three cases and a short topical review. *Acta Anaesthesiol Scand.* 2010;54(6):777–80. Available from: <http://dx.doi.org/10.1111/j.1399-6576.2010.02240.x>
- Forauer AR, Theoharis C. Histologic Changes in the Human Vein Wall Adjacent to Indwelling Central Venous Catheters. *Journal of Vascular and Interventional Radiology.* 2003;14(9):1163–8. Available from: <http://dx.doi.org/10.1097/01.rvi.0000086531.86489.4c>
- Kohler TR, Kirkman TR. Central venous catheter failure is induced by injury and can be prevented by stabilizing the catheter tip. *J Vasc Surg.* 1998;28(1):59–66. Available from: [http://dx.doi.org/10.1016/s0741-5214\(98\)70200-9](http://dx.doi.org/10.1016/s0741-5214(98)70200-9)
- Wildgruber M, Lueg C, Borgmeyer S, Karimov I, Braun U, Kiechle M, et al. Polyurethane versus silicone catheters for central venous port devices implanted at the forearm. *Eur J Cancer.* 2016;59:113–24. Available from: <http://dx.doi.org/10.1016/j.ejca.2016.02.011>



This work is licensed under a Creative Commons Attribution